



## Bleaching primary teeth with 10% carbamide peroxide

David H. Brantley, DDS   Kathryn P. Barnes, RDH   Van B. Haywood, DMD

*Dr. Brantley and Mrs. Barnes are in private practice, Augusta, Georgia; Dr. Haywood is professor, Department of Oral Rehabilitation, School of Dentistry, Medical College of Georgia, Augusta, Georgia. Correspond with Dr. Haywood at vhaywood@mail.mcg.edu*

### Abstract

*Bleaching teeth with 10% carbamide peroxide in a custom-fitted tray has been popular for more than 10 years. However, primary teeth are seldom considered for bleaching due to the need for compliance by the child and the natural whiteness of the primary teeth. This report describes an indication—teeth darkened from trauma—as well as the technique and outcome for bleaching discolored primary teeth. (Pediatr Dent 23:514-516, 2001)*

Bleaching of permanent teeth has enjoyed a renewed interest since the first 1989 publication of the technique originally called Nightguard vital bleaching.<sup>1</sup> This technique applies a 10% carbamide peroxide applied in a custom-fitted tray for a number of days or weeks, preferably using overnight wear. Early reports cite the use on children as young as 10 years of age, primarily for brown fluorosis or genetically yellow permanent teeth.<sup>2</sup> Primary teeth generally are not considered for bleaching since they typically are very white. However, trauma to the anterior primary teeth between eruption and exfoliation can result in a darkening of the teeth and an esthetic compromise for the young child.<sup>3</sup>

Treatments to date have included composite crowns or bonding to cover the brown discoloration, or pulpectomy therapy and internal bleaching or composite restorations to lighten the teeth. These techniques require a high level of patient compliance and dental skill and incur a significant fee. The esthetic outcome does not always warrant the time, patient management issues and expense, especially since the life of the tooth is limited.

The purpose of this case report is to present another option for altering the color of discolored primary teeth associated with trauma.

### Case description

A 4-year-old female sustained trauma to her two maxillary primary central incisors from falling and hitting her mouth on an outside playground slide. Upon emergency examination, both primary central incisor teeth were mobile, but no other problems were revealed radiographically or clinically (Fig 1). At a recall examination approximately 5 months later, both central incisors had become discolored (Fig 2). Over the next month, the teeth became progressively darker. Radiographs continued to be negative (Fig 3).

There was no evidence radiographically of internal or external resorption, nor any periapical or periradicular osseous radiolucencies. There was no evidence of widened periodontal ligament or of root fractures, nor any evidence of calcification

of the pulp spaces. Clinically, there was no mobility, nor was there sensitivity to percussion or digital manipulation. The color change seemed typical for concussion injuries to primary teeth. Pulp testing was not attempted, since this is seldom valid for primary teeth, so the teeth could have been vital or non-vital. Tooth discoloration is not indicative of pulpal status.<sup>4</sup> The child reported that other children and adults were now commenting about her dark teeth (Fig 4).

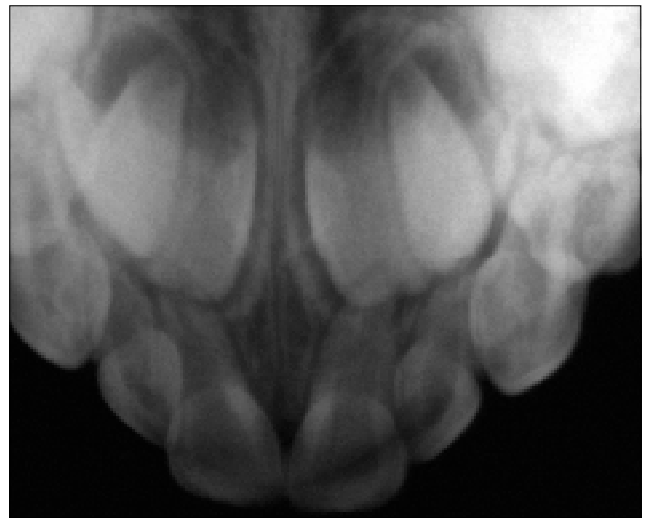


Fig 1. Radiograph of maxillary teeth taken two weeks after trauma

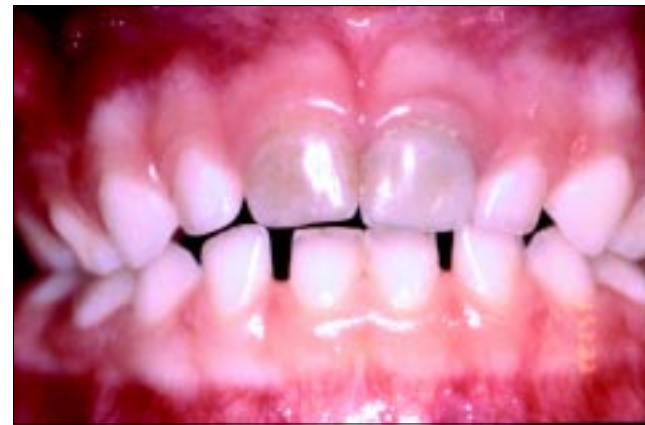

Fig 2. Maxillary primary central incisors have been darkened following trauma

Received July 3, 2001   Revision Accepted November 15, 2001

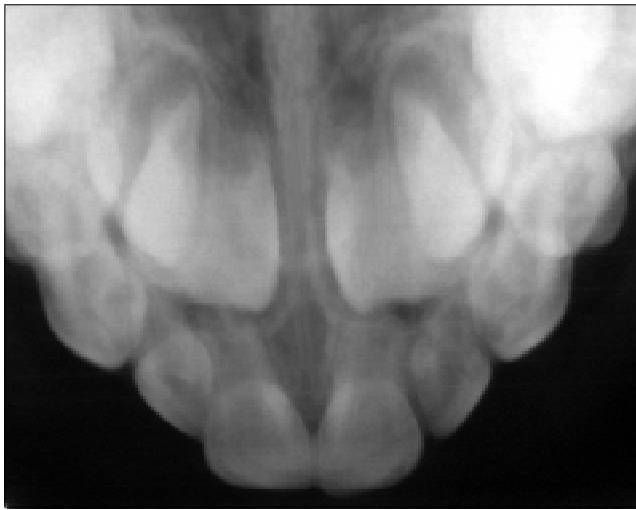


Fig 3. Radiograph of maxillary teeth indicate no pathosis in periapical region

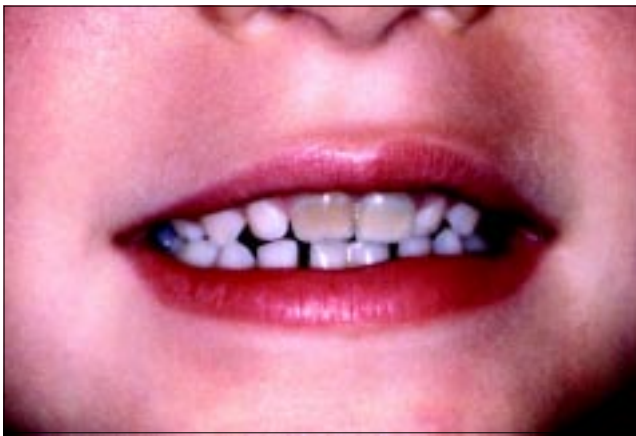

Fig 4. Darkened maxillary primary central incisors are a distraction to the smile

Treatment options were discussed, including no treatment, composite veneers or a pulpectomy with composite crowns. However, none of those treatments would necessarily improve the color without some sacrifice of overall esthetics or unnecessary treatment. With the consent of the parents, one of whom was an oral surgeon, the decision was made to attempt vital bleaching with 10% carbamide peroxide in a custom-fitted tray as had been reported successful for adult teeth darkened by trauma.<sup>5</sup>

An alginate impression was made of the maxillary arch, and a non-scalloped, no-reservoir bleaching tray fabricated from a soft thermoplastic material (Sof-tray, Ultradent Products Inc., South Jordan, UT). An American Dental Association-approved 10% carbamide peroxide was chosen which was water-soluble and pleasant-tasting (Platinum Overnight, Colgate Oral Pharmaceuticals, Canton, MA). The parents and patient were given instructions in the application techniques and time of wear. The patient initially applied a small amount of the bleaching material for one hour per day for two weeks. Some improvement was noted, but not complete lightening.

The patient had experienced no sensitivity, and compliance was excellent. Lack of sensitivity could have been an indication of the teeth being non-vital, or could have been the normal

response for a vital tooth in this patient. With no contraindications for continued treatment, the patient then applied the bleaching solution in the tray overnight every third night for two more weeks. Total wear time was approximately 47 hours. At the three-month recall appointment, the teeth had lost most of their discoloration (Fig 5) and were very pleasing to the patient and the parents (Fig 6).

The teeth were exfoliated at their normal time, approximately two years later, with no further complications. The parents reported there was some slight darkening just prior to exfoliation, but it did not seem to be noticeable to the child. When the permanent teeth erupted, there was no apparent damage to the permanent teeth.

## Discussion

In the previously reported situations of adult teeth darkened by trauma, the vitality was not considered of primary significance. If there were no clinical symptoms of pain or mobility, and no radiographic signs of periapical radiolucencies or resorption, then bleaching was indicated whether or not the tooth tested vital or non-vital.<sup>6</sup> If the tooth subsequently required endodontic therapy, there is no additional problem created from the previous bleaching, nor is there any indication that bleaching with this low concentration of peroxide would precipitate the need for endodontic therapy.

Pediatric literature had indicated that 72% of primary teeth post-concussion injury failed to develop any radiographic and/or clinical evidence of pathosis, but remained asymptomatic and no treatment was required.<sup>7</sup> There is some controversy over the significance of discoloration and the pulpal status from trauma,<sup>8</sup> but discoloration is not indicative of vitality or lack of vitality.<sup>9</sup> Hence, bleaching was reasonable to consider in the absence of any negative radiographic or clinical signs or symptoms.

With primary teeth, there is always the concern for the effect of the trauma on the formation of the permanent teeth. However, there does not seem to be any indication that this low concentration of 10% carbamide peroxide will affect the tooth whether it is vital or non-vital, nor that it would cause a non-vital tooth to become symptomatic. Normal recall schedules for traumatized teeth should be followed whether bleaching is attempted or not.

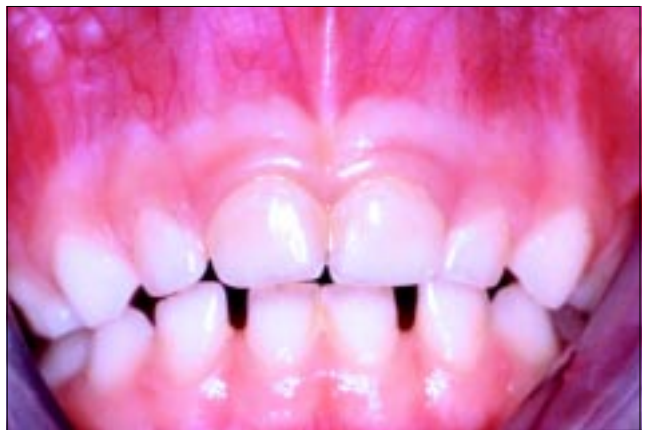

Fig 5. Maxillary primary central incisors are lightened somewhat by bleaching with 10% carbamide peroxide in a custom-fitted tray for 47 total hours

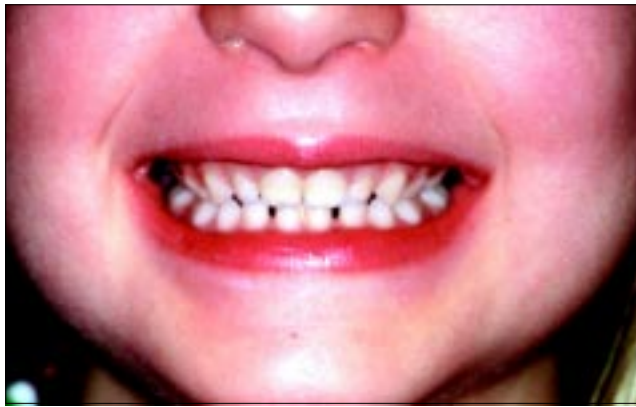

Fig 6. The four-year old child's smile is more esthetically pleasing with lightened teeth

With any treatment of children, concern should always be for dosage of material. The use of a non-scalloped tray design minimized the amount of material used. It has been found that only a minimum material is required for bleaching,<sup>10</sup> more like applying Vaseline to the teeth in a "thin-film" technology approach. The use of a non-scalloped tray also served to contain the material better, since this type of tray "seals" against the gingivae. However, there is little concern of ingestion for the minimal amount of material used during this treatment, since this 10% carbamide peroxide material has been used in newborn infants for throat infections.<sup>11</sup> In that report, 10 drops of a 10% carbamide peroxide were applied in 25 newborn infants after each feeding for 2 to 7 days to reduce the treatment time with no problems. This treatment is a standard protocol at pediatric hospitals today. Other uses, including use for three years as a mouth rinse in orthodontic patients to prevent white spot lesions, have demonstrated safety in young children.<sup>12</sup>

This technique offers the dental office a conservative treatment approach to lighten teeth darkened by trauma. The resulting esthetic outcome is very natural, and relatively easy to achieve. If this treatment not be successful, all other treatment options are still available. Should the teeth have pulpal problems requiring intervention, the treatment post-bleaching is the same as that which would have been used had those problems existed pre-bleaching.

Generally, the aesthetic outcome of bleaching natural teeth exceeds that of composite veneers or crowns due to the more

natural appearance of the enamel as compared to restorative materials. To mask dark teeth, composite resin typically must be opaque and thick, which may compromise esthetics. This treatment achieved very reasonable results in a very compliant child with supportive parents.

### Acknowledgements

This information was presented at the American Academy of Pediatric Dentistry annual meeting in Atlanta, Georgia, May 2001.

### References

1. Haywood VB, Heymann HO. Nightguard vital bleaching. *Quintessence Int* 20:173-176, 1989.
2. Haywood VB. History, safety, and effectiveness of current bleaching techniques and applications of the nightguard vital bleaching technique. *Quintessence Int* 23:471-488, 1992.
3. Wilson CF. Management of trauma to primary and developing teeth. *Dental Clinics of North America* 39:133-167, 1995.
4. Borum MK, Andreasen JO. Sequelae of trauma to primary maxillary incisors. I. Complications in the primary dentition. *Endod-Dent-Traumatol* Feb;14(1):31-44, 1998.
5. Haywood VB. Bleaching of vital and nonvital teeth. *Current Opinion in Dentistry* 2:142-149, 1992.
6. Haywood VB, Heymann HO. Response of normal and tetracycline-stained teeth with pulp-size variation to nightguard vital bleaching. *J Esthet Dent* 6(3):109-114, 1994.
7. Sonis A. Longitudinal study of discolored primary teeth and effect on succedaneous teeth. *J Pedod* 11:247-252, 1987.
8. Holan G, Fuks AB. The diagnostic value of coronal dark-gray discoloration in primary teeth following traumatic injuries. *Pediatr Dent* 18:224-227, 1996.
9. Fried I, Erickson P. Anterior tooth trauma in the primary dentition: incidence, classification, treatment methods, and sequelae: a review of the literature. *ASDC Journal of Dentistry for Children* 62:256-261, 1995.
10. Haywood VB. Are reservoirs necessary? *J Esthet Dent* 11(1):3, 1999.
11. Dickstein B. Neonatal oral candidiasis: Evaluation of a new chemotherapeutic agent. *Clinical Pediatrics* 3(8):485-488, 1964.
12. Haywood VB, Heymann HO. Nightguard vital bleaching: how safe is it? *Quintessence Int* 22:515-523, 1991.